



collegebatch.com

click to campus

## INI CET 2024 Question Paper

Graduate Aptitude Test in Engineering (GATE)

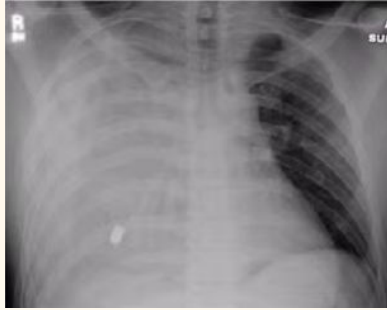Paper	Page No.
INI CET 2024 Question Paper - Set 1	2 - 10
INI CET 2024 Question Paper - Set 2	11 - 17

Download more INI CET Previous Year Question Papers: [Click Here](#)

# INI CET 2024 Question Paper

---

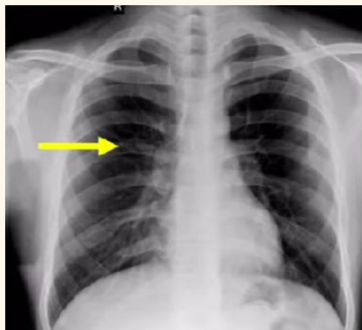
Ques 1. A pt with stab injury to chest. Supine X ray given. Diagnosis



- a. Right hemothorax
- b. Diaphragmatic rupture
- c. Pulmonary contusion
- d. Rt pneumothorax.

Ans. a

Ques 2. The arrow is pointing to



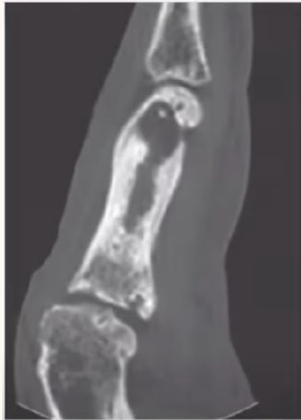- a. Pulmonary artery
- b. Costal cartilage
- c. Posterior rib
- d. Anterior rib

Ans. c

- Ques 3. Mt Fuji sign is seen in**
- a. Tension pneumothorax**
  - b. Tension pneumomediastinum**
  - c. Tension pneumocephalus**
  - d. tension pneumoperitoneum**

**Ans. c**

**Ques 4. Diagnosis**



- a. Osteosarcoma**
- b. Ewings**
- c. Chronic osteomyelitis**
- d. Osteomalacia**

**Ans. c**

**Ques 5. True about CT**

- a. Water has HU 0**
- b. Unfiltered xray beam is used**
- C. CT head dose is 20 msv**
- d. First investigation for gall stones**

**Ans. A**

**Ques 6. Contrast that can be given in pts of chronic kidney disease**

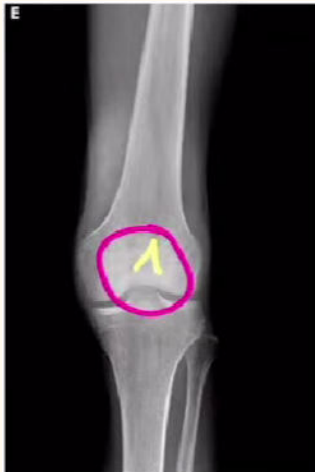- a. Ioniciodinated contrast**

- b. non ionic Iodinated contrast
- c. ultrasound contrast
- d. gadolinium

Ans. c

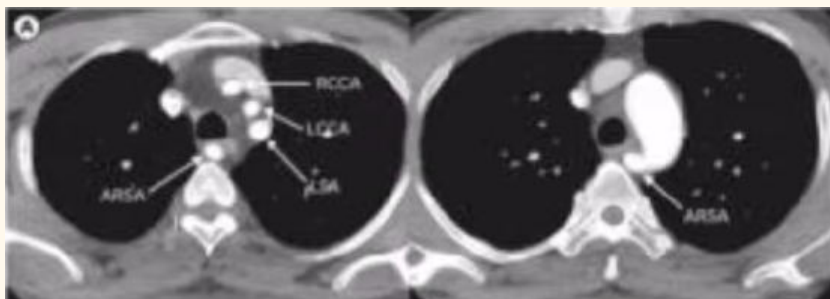
**Ques 7. Diagnosis**

- a. patella fracture
- b. Rheumatoid arthritis
- c. Hemarthrosis
- d. Tibial condyle fracture



Solu. A

**Ques 8. Anatomic variation seen in this CT**



- a. Tracheal diverticulum
- b. Double esophagus

- C. ARSA
- d. Right aortic arch

Ans. c

**Ques 9. Which of the following is not typically seen in allergic rhinitis?**

- a. Otto veraguth folds
- b. Allergic salute
- c. Allergic shiner
- d. Denis Morgan lines

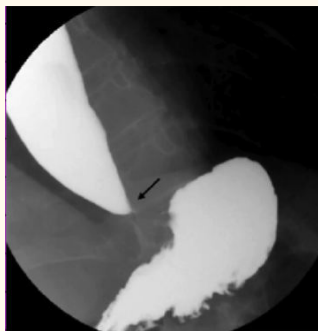
Ans. a

**Ques 10. What is the most likely diagnosis for a 13- year-old boy presenting with right-sided nasal obstruction and recurrent epistaxis for the past 6 months?**

- a. JNA (Juvenile Nasopharyngeal Angiofibroma)
- b. Allergic Rhinitis
- c. Coagulation Disorder
- d. Antrochoanal Polyp

Ans. d

**Ques 11. Symptoms indicate which condition: weight loss, dysphagia, halitosis, sign on X-ray?**



- a. Achalasia
- b. Esophageal Cancer

- c. Gastroesophageal Reflux Disease (GERD)
- d. Zenker's Diverticulum

**Ans. a**

**Ques 12. Which procedure should not be performed in an 8-year-old with bilateral sensorineural hearing loss?**

- a. Tonsillectomy
- b. Adenoidectomy with grommet insertion
- c. Myringotomy
- d. Cochlear implantation

**Ans. b**

**Ques 13. ER, PR are what type of markers?**

- a. Diagnostic
- b. Prognostic
- c. Predictive
- d. Surrogate molecular marker

**Ans. a**

**Ques 14. Purpose of Downes criteria in neonatology assessment?**

- A. To assess respiratory distress syndrome (RDS)
- B. To evaluate Downey cells in blood samples
- C. To measure Silverman-Anderson score for respiratory distress
- D. To calculate Vidyasagar scoring system for neonatal assessment

**Ans. a**

**Ques 15. Declaration of Oslo, 1970 primarily concerned with?**

- A. Torture

- B. Abortion**
- C. Environmental protection**
- D. Nuclear disarmament**

**Ans. a**

**Ques 16. Which is NOT a risk factor of cholangiocarcinoma?**

- A. Hepatitis B (hepatitis B virus infection)**
- B. Primary Sclerosing Cholangitis (PSC)**
- C. Caroli Disease**
- D. Opisthorchis viverrini infection**

**Ans. A**

**Ques 17. Which is NOT included in criteria to diagnose autism?**

- A. Cognitive delays**
- B. Failure to communicate effectively**
- C. Repetitive behaviors or restricted interests**
- D. Impaired social interactions**

**Ans. A**

**Ques 18. Fluid of choice in resuscitation in children?**

- A. 5% dextrose and normal saline**
- B. 5% dextrose and N/4 saline**
- C. 10% dextrose and normal saline**
- D. 5% dextrose and N/2 saline**

**Ans. A**

**Ques 19. Non-spreading variety of vitiligo?**

- A. Focal**
- B. Acrofacial**
- C. Segmental**
- D. None of the above**

**Ans. A**

**Ques 20. What is the preferred contrast agent for patients with chronic kidney disease?**

- A. Ionic iodinated**
- B. Non-ionic iodinated**
- C. Ultrasound (US)**
- D. Gadolinium**

**Ans. C**

**Ques 21. Procedure not recommended in an 8-year-old with bilateral sensorineural hearing loss?**

- A. Adenoidectomy with grommet insertion**
- B. Tonsillectomy**
- C. Myringotomy**
- D. Cochlear implantation**

**Ans. a**

**Ques 22. A 30-year-old female patient with chronic hypertension is experiencing postpartum hemorrhage (PPH).**

- A. Oxytocin**
- B. Methyl ergotamine**
- C. PGF<sub>2a</sub> (Prostaglandin F<sub>2a</sub>)**
- D. Misoprostol**

**Ans. b**

**Ques 23. A 36-week pregnant female presents with hypertension, visual disturbances, headache, and proteinuria (3+).**

- A. IV labetalol, magnesium sulfate, delivery**
- B. IV labetalol, corticosteroids**
- C. IV labetalol, corticosteroids only**



**D. IV labetalol, magnesium sulfate**

**Ans. D**

**Ques 24. A mother with O negative blood group and a father with B positive blood group have a baby.**

- A. The baby has O positive blood group and antibodies negative.**
- B. The baby has O positive blood group and antibodies positive.**
- C. The baby has O positive blood group, and the Direct Coombs Test (DCT) is positive.**
- D. The baby has AB positive blood group. and the Direct Coombs Test (DCT) is negative.**

**Ans. A**

**Ques 25. Which mineral is important for fertility in males?**

- A. Zinc**
- B. Selenium**
- C. Nickel**
- D. Copper**

**Ans. A**

**Ques 26. What is the correct dose regimen for antenatal corticosteroids?**

- A. Dexamethasone 6 mg every 12 hours, 4 times**
- B. Dexamethasone 12 mg every 12 hours, 2 times**
- C. Betamethasone 12 mg every 12 hours, 4 times**
- D. Betamethasone 6 mg every 12 hours, 2 times**

**Ans. A**

**Ques 27. An 18-week fetus was suspected to have neural tube defects and Down syndrome based on the quadruple markers test.**

- A. Chorionic Villus Sampling (CVS)**

- B. Amniocentesis**
- C. Non-Invasive Prenatal Testing (NIPT)**
- D. Anomaly Scan**

**Ans. D**

**Ques 28. A 28-year-old female presents with abdominal pain and vaginal bleeding for the past 2 days.**

- A. Abruptio placenta**
- B. Ruptured ectopic pregnancy**
- C. Placenta previa**
- D. Missed abortion**

**Ans. B**

**Ques 29. What is the most common type of hernia in females?**

- A. Direct inguinal hernia**
- B. Indirect inguinal hernia**
- C. Femoral hernia**
- D. Incisional hernia**

**Ans. C**

---

# INI CET 2024 Question Paper Nov 5 (Memory Based)

---

**Question 1. A patient presents to the OPD with the complaints of vertigo which is sudden in onset, sensorineural hearing loss(SNHL), and Tinnitus which lasts minutes to hours with accompanied nausea, vomiting and vagal symptoms. On investigations, there is endolymphatic hypertension present. What is the diagnosis of the patient?(ENT)**

- A. Meniere's Disease**
- B. Endolymphatic Hydrops**
- C. Benign Paroxysmal Positional Vertigo (BPPV)**
- D. Acoustic neuroma**

**Answer. B**

**Question 2. A patient presents to the OPD with complaints of bilateral hearing loss with worsen right ear hearing loss. On examination, the doctor diagnose Otosclerosis and recommends stapedectomy as a final resort to the problem. What would be the findings of Tuning fork tests based on which Doctor recommends Stapedectomy?(ENT)**

- A. Renne's Test - positive; Weber's Test - lateralized to left ear**
- B. Renne's Test - positive; Weber's Test - lateralized to right ear**
- C. Renne's Test - negative; Weber's Test - lateralized to left ear**
- D. Renne's Test - negative; Weber's Test - lateralized to right ear**

**Answer. D**

**Question 3. A patient presents to the OPD with complaints of hearing loss and can understand only shouted or amplified speech. What will be the Degree of impairment according to the WHO classification of Ability to understand speech?(ENT)**

- A. Mild hearing loss**
- B. Moderate hearing loss**
- C. Severe hearing loss**
- D. Profound hearing loss**

**Answer. C**

**Question 4. A patient presents to the OPD with complaints of bleeding from nose, nasal obstruction, and difficulty in breathing. He gave the history of bathing in the local pool near his house. On examination, red polypoidal mass with whitish dots on the surface is observed, Based on the history, examination and given histopathological image, what will be the diagnosis of the patient?(ENT)**

- A. Rhinosporidiosis**
- B. Basal Cell Carcinoma**
- C. Rhinoscleroma**
- D. Lupus Vulgaris**

**Answer. A**

**Question 5. Blue Colour vacutainer for plasma glucose estimation consists of which anticoagulant?**

**Answer. NaF**

**Question 6. Upon class switching a specific class of antibody is produced IgM and IgD expressed concomitantly because?**

**Answer.** RNA Splicing

**Question 7. Sickle Cell Anemia (Pathology)**

- A. Low Mechanical Strength, High Osmotic Fragility**
- B. High Mechanical Strength, High Osmotic Fragility**
- C. Low Mechanical Strength, Low Osmotic Fragility**
- D. High Mech and high, Low Osmotic Fragility**

**Answer.** A

**Question 8. What is not used for identification of a dead body except?(Forensic Medicine)**

- A. Muscle,**
- B. Blood,**
- C. Nail,**
- D. Hair)**

**Answer.** C

**Question 9. What can be the poisoning case if a young aile with suspected poisoning with pinpoint pupils? (Forensic Medicine)**

**Answer.** Opioid

**Question 10. What kind of wound is not expected if a person is brought to the emergency after a road accident with stable vitals? (Forensic Medicine)**

- A. Chop Wounded**
- B. Multiple Bruises**
- C. Graze Abrasion**
- D. Laceration**

**Answer.** Chop Wounded

**Question 11. Cause that results in non-scarring alopecia?  
(Dermatology)**

**Answer.** Alopecia areata, Telogen effluvium, Androgenic Alopecia

**Question 12. male with the age of 45 years appears with recurrent blisters and oral ulcers fir 3 years. What is the diagnosis?  
(Dermatology)**

**Answer.** Pemphigus Vulgaris

**Question 13. An immunocompromised individual appears with a corrugated white lesion on the side of the tongue which does not wipe off. What would be the cause? (Dermatology)**

**Answer.** HSV 1

**Question 14. What will be your recommendation if an obese female with a BMI of 29, amenorrhea, and hirsutism comes to your hospital?  
(Dermatology)**

**Answer.** OCP and dietary measure

**Question 15. A baby the age of 18 days was brought with a cough and fever and had vesicles over the trunk and upper limbs. Mother too had a genetic ulcer 1 year back but they have resolved no. This biopsy of vesicles shows multinucleate giant cells. What is the diagnosis called? (Dermatology)**

**Answer. Herpes simplex**

**Question 16. A vegetarian Patient with MCV -110, Hb - 10 gm% will have? (Pathology)**

**Answer. Megaloblastic anaemia**

**Question 17. Where the serum transferrin saturation level is low in?(Pathology)**

**Answer. IDA**

**Question 18. Among the given options which is not a criteria for metabolic syndrome? (Pathology)**

- A. Blood Glucose**
- B. HDL**
- C. ABD Circumference**
- D. BP**

**Answer. ABD Circumference**

**Question 19. What is expected to be the disorder when a female aged 26 years provides the medical history of their father and sister having the same bleeding disorders? (Pathology)**

**Answer. Hemophilia A**

**Question 20. Hawkin classification used for what?(Pathology)**

**Question 21. There was a question asked by Brugada Syndrome.**

**Question 22. What is not helpful in the DNA double-strand break repair?**

**Question 23. There was a question asked about Sinusitis where ENT and Optha were combined.**

**Question 24. A female presented with menorrhagia reported bleeding disorders for her father and sister. Which of the following was the diagnosis with an autosomal dominant pattern?**

**Question 25. Sweat chloride and Pancreatic level of Cl is cystic Fibrosis?**

**Question 26. One question was asked form the HBsAg Screening.**

**Question 27. What helps in increasing in size of electrophoresis in Nephrotic syndrome?**

**Question 28. In CSF values of protein, glucose and, lymphocytes were given and you have to find out the type of infection affecting the patients.**

**Question 29. What type of cancer is not a c/i for Liver transplantation?**

**Question 30. Which chemo mediator is responsible for the formation of Langerhans cells in TB.**



**Question 31. What is the most important prognostic factor of breast cancer?**